

## Wound VAC for Fournier's gangrene: A new technique for applying a vacuum-assisted closure device on multiple wound sites using minimal connectors

Raymond Pryor III, MD<sup>1</sup>, Dorothy Sparks, MD<sup>1</sup>, Daniel Chase, MD<sup>1</sup>, and Gregg Bogen, MD<sup>1</sup>

<sup>1</sup> Northside Medical Center, Northeast Universities College of Medicine, Youngstown, OH, USA

### ABSTRACT

Use of a vacuum-assisted closure (VAC) device has been associated with accelerated development of granulation tissue, earlier re-epithelialization of wounds, and faster closure of complex wounds than traditional dressings. Extensive and multiple wounds can present a challenge to traditional VAC use, especially when the wounds are separated by areas of normal tissue. A 56-year-old obese diabetic female presented with a lesion on her inner thigh. She had a 2 cm lesion on her inner thigh that was draining a grayish fluid. Extensive crepitus was palpated on both thighs and her perineum. She was diagnosed with an advanced **Fournier's gangrene**. An extensive debridement of all involved tissue was performed, including her labia and perineum, mons pubis, buttocks, left leg to the level of the knee, and right leg to mid-thigh level. We elected to use a VAC device for wound management. Given the complexity and extent of her wound, the traditional method of one sponge and suction tubing per wound would have required several **negative-pressure devices**. We devised a method using **bridges of VAC foam** that was effective for closing this complex series of wounds, requiring only a single negative-pressure device and two connectors.

**Cite as:** Pryor III R, Sparks D, Chase D, Bogen G. Wound VAC for Fournier's gangrene: A new technique for applying a vacuum-assisted closure device on multiple wound sites using minimal connectors. OPUS 12 Scientist 2009;3(3):47-49.

**Correspondence to:** R. Pryor III, MD. Northside Medical Center, Northeast Ohio Universities College of Medicine, 500 Gypsy Lane, Youngstown, OH 44501 USA. Email: [forumflush@gmail.com](mailto:forumflush@gmail.com)

**Keywords:** Wound VAC, Fournier's Gangrene, Complex soft tissue infection, Necrotizing fasciitis, Wound management.

### INTRODUCTION

Use of a **vacuum-assisted closure (VAC)** device has been associated with accelerated development of granulation tissue, earlier re-epithelialization of wounds, and faster closure of complex wounds than traditional dressings.<sup>1</sup> Since their introduction, VAC devices have been effectively used to close a wide variety of wounds in many anatomic locations.

Extensive and multiple wounds can present a challenge to traditional VAC use, especially when the wounds are separated by areas of normal tissue. When multiple sponge application sites are involved, it can be difficult to attach them to the same vacuum device. Sometimes two or even three vacuum pumps are needed, greatly increasing the cost and complexity of wound care.

We present the case of a patient with **necrotizing fasciitis** who required extensive wound debridement whom we were able to manage with a single vacuum pump using a **novel technique of bridging between the wounds with foam sponges**. We devised a

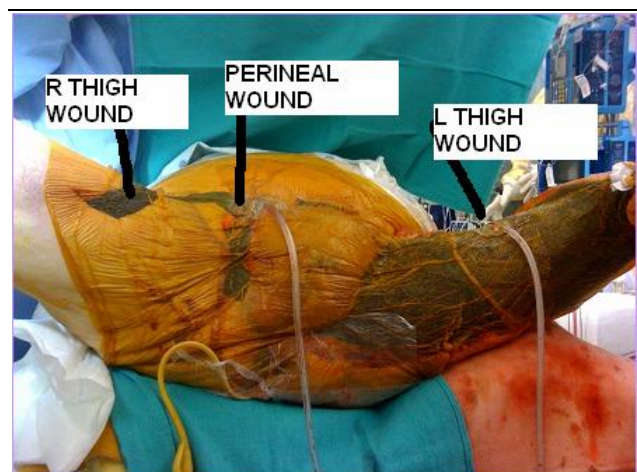
method, described below, that was effective for closing this complex series of wounds, requiring only a single negative-pressure device and two connectors.

### CASE REPORT

A 56-year-old obese poorly controlled diabetic female presented to our emergency department complaining of a lesion on her inner thigh. She noticed the spot four days previously, and associated it with shaving. Since then, it had grown in size and pain, causing her to seek medical attention.

On exam, the patient had a 2 cm lesion on her inner thigh that was draining a grayish fluid. Extensive crepitus was palpated on both thighs and her perineum. She was diagnosed with an advanced **Fournier's gangrene**, and was taken to the operating room emergently for debridement.

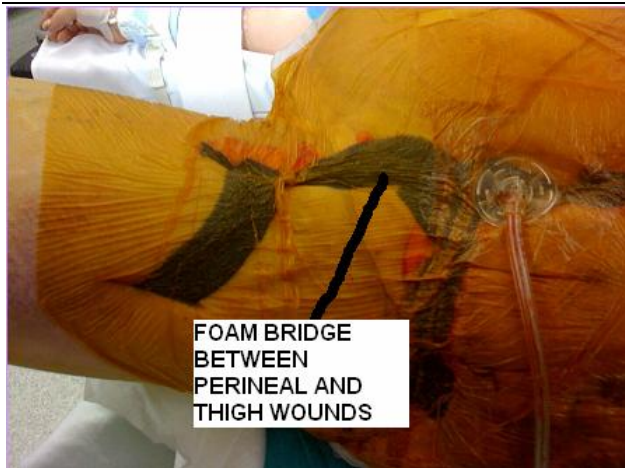An extensive debridement of all involved tissues was performed, including her labia and perineum, mons pubis, buttocks, left leg to the level of the knee, and right leg to mid-thigh level. A diverting colostomy was also performed at that time. We elected to use the **wound VAC device** for temporary coverage of her wounds. Given the complexity and extent of her wound, the traditional method of one sponge and suction tubing per wound would have required several **negative-pressure devices**. While it is possible to connect more than one sponge to the device via a Y-connector, several machines would still have been required. We devised a method, described below, that was effective for closing this complex series of wounds, requiring only a single **negative-pressure device** and two connectors. The patient was taken to the Surgical Intensive Care Unit (SICU) post-operatively.



**Figure 1.** An extensive debridement of necrotizing soft tissue infection with VAC application and bridge connections.

Serial exams were performed and 12 hours later she was found to have new crepitus present on her legs at knee level. She was taken back and further debridement was performed. Our *wound VAC technique* was again re-applied.

A return to the operating room the next day revealed purulence in the inguinal canal. Further debridement was done, the *VAC* was once again successfully re-applied, and she returned to the SICU. Despite aggressive therapy, the patient eventually succumbed to multiple organ failure. Details of our *VAC* application technique are described below.



**Figure 2.** Foam bridge connection between non-contiguous surgical sites distributes negative pressure suction.

## TECHNIQUE

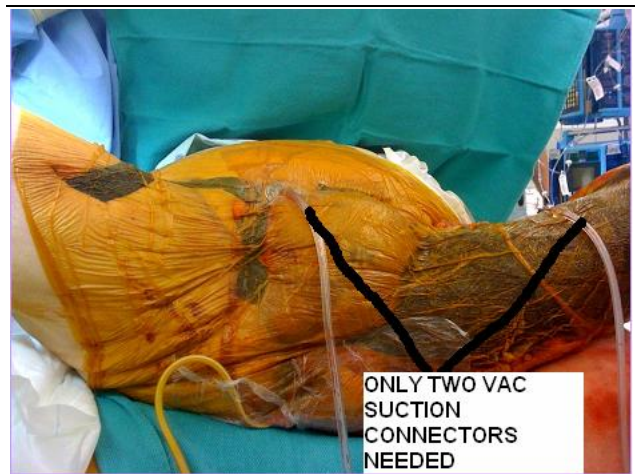Each wound bed was fitted with a sponge cut to size (**Figure 1**). Since several of the wounds were separated by areas of normal skin but connected with *subcutaneous tunnels*, a strip of sponge, along with a large Penrose drain, was placed in the tunnels between the wounds. Strips of sponge were placed over the skin connecting each individual wound (**Figure 2**).

Instead of using the standard occlusive plastic sheets provided in the *VAC* kit, several large iodine impregnated film drapes were then placed over the entire wound bed. These were significantly larger and allowed easier coverage of the wound with less material. The two largest wounds were then selected to attach to the *negative-pressure device*. A hole was made in the drape in the center of these wounds and the suction tubing was attached using the manufacturer's applicator. The tubing was then connected to the negative-pressure device using a Y-connector and 200 mm Hg negative suction was then applied. Once suction was applied, the sponges in all wound sites were contracted well and maintained suction equally. The foam bridges allowed the suction to be distributed throughout all the wound beds without having to use multiple vacuum devices (**Figure 3**). This technique was used in repeatedly, each time attaining success in maintaining suction throughout all wound beds. By using this method, we simplified the care of this wound by having only one machine attached to the patient, reducing the number of lines, simplifying nursing care, and reducing the cost to the patient.

## DISCUSSION

Wound *VAC* therapy became commercially available in 1995.<sup>2</sup> The wound *VAC* device is a modified dressing consisting of a sponge that sits directly in the wound bed that is secured with an occlusive dressing. Suction tubing is then attached through an opening created in the occlusive dressing, effectively maintaining a closed system. This suction tubing is then attached to a *negative-pressure device*.

The *wound VAC* has been shown to have a number of advantages for wound care. The watertight arrangement simplifies wound care and prevents drainage onto unaffected areas. Infected fluid is continually drained from the wound bed, allowing the *VAC* dressing to be changed less frequently, such as every two or three days. Because the dressing is less cumbersome and bulky, the *VAC* facilitates early ambulation.<sup>3</sup>



**Figure 3.** Despite extensive wounds, bridge therapy can limit the number of connectors necessary for negative pressure wound closure.

Cellular-level benefits of *VAC* therapy have also been demonstrated. Application to traumatic wounds has been shown to lead to increased local IL-8 and VEGF concentrations. This may trigger accumulation of neutrophils, angiogenesis, and may accelerate neovascularization.<sup>4</sup> The *VAC* has also been shown to increase local blood flow, reduce edema, stimulate formation of granulation tissue, stimulate cell proliferation, reduce matrix metalloproteinases, and reduce bacterial load. It is hypothesized that micromechanical forces exerted by the *VAC foam* may promote cell division, but this has not been proven.<sup>2</sup>

There have been several descriptions of the *VAC* being used in necrotizing soft tissue infections, and *VAC therapy* has characteristics particularly suited to such devastating extensive infections. The complexity of wound care can be simplified for these patients. For example, Huang *et al* demonstrated that the *VAC technique* was effective in managing limb wounds in necrotizing fasciitis. The overall cost was higher, but morbidity and time required to care for the wounds was significantly lower.<sup>5</sup>

*VAC* can be successfully applied to circumferential extremity wounds.<sup>6</sup> Several reports of successful *VAC* use in *Fournier's*

*gangrene* have been published.<sup>3,7-8</sup> Advantages cited were: (a) reduction in the number of required surgical debridements; (b) debriding, cleaning, and preparing the wounds for a single-stage reconstruction after the initial debridement; and (c) as a barrier to fecal soilage when used in the genitourinary region.<sup>7-8</sup>

The *VAC* has also been used as a bridge to skin grafting, and then on the grafts themselves afterwards.<sup>3</sup> In these instances, the *VAC* actually helps skin graft take, especially over large curved areas of the body, by keeping the graft in place and reducing fluid or hematoma under the graft. Successful use has been reported in up to 18 % body surface area split thickness skin grafts.<sup>9</sup>

When placing *VACs* over large or multiple wounds, an increased pressure setting of 150-200 cmH<sub>2</sub>O may be required depending on the surface area of the distributive wound bed. Inability to maintain a vacuum seal or control wound drainage would indicate *VAC* failure, and other methods of wound management should be tried. Also, *VAC* therapy should be avoided where there is exposed mucosal surface, such as bowel or bladder.

Although not utilized in our case, topical antimicrobials such as silver sulfadiazine have been used with some success in the management of necrotizing soft tissue infections. Proponents of this technique note that most necrotizing soft tissue infections have flora that are sensitive to the common topical antimicrobials.<sup>10</sup> Application of such agents could certainly be used in conjunction with a *VAC* dressing.

To minimize the risk of skin necrosis from the foam bridges, we changed the *VAC* dressing every 12 to 24 hours instead of the standard 72 hours. This also allowed for frequent re-examination of the wounds to ensure no further infection was present. Another method of avoiding skin damage is to place petroleum gauze or another piece of bio-occlusive dressing on exposed healthy skin beneath the sponge. Based on these practices, a foam bridge technique is best suited to patients who require short-term serial debridements with temporary *VAC* closure, such as necrotizing soft tissue infections.

## CONCLUSIONS

*Negative pressure wound therapy using foam bridge connectors* is an effective closure technique for complex wounds which might otherwise require multiple suction devices. *VAC* therapy has been successfully utilized in necrotizing soft tissue infections previously, but our novel technique of connecting the separated wounds with foam bridges allowed us to use a single vacuum pump, simplifying wound care and saving costs.

## REFERENCES

- [1] Cipolla J, Baillie DR, Steinberg SM, Martin ND, Jaik NP, Lukaszczyk JJ, Stawicki SP. Negative pressure wound therapy: unusual and innovative applications. *OPUS 12 Scientist* 2008;2(3):15-29.
- [2] Preston G. An overview of topical negative pressure therapy in wound care. *Nursing Standard* 2008;23:62-68.
- [3] Kumar S, O'Donnell ME, Khan K, Dunne G, Carey PD, Lee J. Successful treatment of perineal necrotizing fasciitis and associated pubic bone osteomyelitis with the vacuum assisted closure system. *World Journal of Surgical Oncology* 2008;6:67.
- [4] Labler L, Rancan M, Mica L, Harter L, Mihic-Probst D, Keel M. Vacuum-assisted closure therapy increases local interleukin-8 and vascular endothelial growth factor levels in traumatic wounds. *J Trauma* 2009;66:749-757.
- [5] Huang WS, Hsieh SC, Hsieh CS, Schoung JY, Huang T. Use of vacuum-assisted wound closure to manage limb wounds in patients suffering from acute necrotizing fasciitis. *Asian J Surg* 2006;29:135-139.
- [6] Barendse-Hofmann MG, van Doorn L, Steenvoorde P. Circumferential application of VAC on a large degloving injury on the lower extremity. *J Wound Care* 2009;18:79-82.
- [7] Cuccia G, Mucciardi G, Morgia G, d'Alcontres FS, Gali A, Cotrufo S, Romeo M, Magno C. Vacuum-assisted closure for the treatment of Fournier's gangrene. *Urologia Internationalis* 2009;82:426-431.
- [8] Tucci G, Amabile D, Cadeddu F, Milito G. Fournier's gangrene wound therapy: our experience using VAC device. *Langenbecks Arch Surg* 2009;394:759-760.
- [9] Steinstraesser L, Sand M, Steinau H. Giant VAC in a patient with extensive necrotizing fasciitis. *The International Journal of Lower Extremity Wounds* 2009;8:28-30.
- [10] Barillo DJ, McManus AT, Cancio LC, Sofer A, Goodwin CW. Burn center management of necrotizing fasciitis. *J Burn Care Rehabil.* 2003;24(3):127-132.

Permission to make digital or hard copies of all or part of this work for personal or classroom use is granted without fee provided that copies are not made or distributed for profit and that copies bear this notice and the full citation on the first page. To copy otherwise, or republish, to post on servers or to redistribute to lists, requires prior permission and/or a \$5.00 fee.

*OPUS 12 Scientist* – A Twice Yearly Publication of *OPUS 12 Foundation*  
© 2007–2010 *OPUS 12 Foundation, Inc.*, Columbus, OH 43235 USA.